

# Retinal microvascular signs in COVID-19

Ralene Sim <sup>1,2</sup>, Gemmy Cheung <sup>1,2</sup>, Daniel Ting <sup>1,2</sup>, Edmund Wong,<sup>1,2</sup>  
Tien Yin Wong <sup>1,2</sup>, Ian Yeo <sup>1,2</sup>, Chee Wai Wong<sup>1,2</sup>

<sup>1</sup>Singapore National Eye Centre, Singapore

<sup>2</sup>Singapore Eye Research Institute, Singapore

## Correspondence to

Dr Ian Yeo, Singapore National Eye Centre, Singapore; ian.yeo.y.s@singhealth.com.sg

Received 19 October 2020

Revised 22 February 2021

Accepted 7 March 2021

## ABSTRACT

**Background/aims** To explore if retinal findings are associated with COVID-19 infection.

**Methods** In this prospective cross-sectional study, we recruited participants positive for COVID-19 by nasopharyngeal swab, with no medical history. Subjects underwent retinal imaging with an automated imaging device (3D OCT-1 Maestro, Topcon, Tokyo, Japan) to obtain colour fundus photographs (CFP) and optical coherence tomographic (OCT) scans of the macula. Data on personal biodata, medical history and vital signs were collected from electronic medical records.

**Results** 108 patients were recruited. Mean age was 36.0±5.4 years. 41 (38.0%) had symptoms of acute respiratory infection (ARI) at presentation. Of 216 eyes, 25 (11.6%) had retinal signs—eight (3.7%) with microhaemorrhages, six (2.8%) with retinal vascular tortuosity and two (0.93%) with cotton wool spots (CWS). 11 eyes (5.1%) had hyper-reflective plaques in the ganglion cell-inner plexiform layer layer on OCT, of which two also had retinal signs visible on CFP (CWS and microhaemorrhage, respectively). There was no significant difference in the prevalence of retinal signs in symptomatic versus asymptomatic patients (12 (15.0%) vs 13 (9.6%), p=0.227). Patients with retinal signs were significantly more likely to have transiently elevated blood pressure than those without (p=0.03).

**Conclusion** One in nine had retinal microvascular signs on ocular imaging. These signs were observed even in asymptomatic patients with normal vital signs. These retinal microvascular signs may be related to underlying cardiovascular and thrombotic alternations associated with COVID-19 infection.

## INTRODUCTION

COVID-19 is a novel coronavirus (SARS-CoV-2), identified as a member of the Coronaviridae family. To date, COVID-19 has affected over 18 million people and caused more than 600 000 deaths worldwide.<sup>1</sup> Although COVID-19 is primarily a respiratory illness best known for its effects on lung tissue, there has been increasing evidence that it may induce a vigorous inflammatory response<sup>2</sup> and a hypercoagulable and prothrombotic state<sup>3–5</sup> which may explain a higher prevalence of cardiovascular events such as acute ischaemic stroke,<sup>6</sup> limb ischaemia<sup>7</sup> and myocardial infarction<sup>8</sup> in patients with COVID-19. However, COVID-19-induced inflammatory and coagulopathic complications on the vascular system of the eye are not well-studied, despite the established associations of retinopathy with other cardiovascular manifestations, including but not limited to hypertension,<sup>9</sup> stroke<sup>10–12</sup> and renal dysfunction.<sup>13</sup>

In a series of 12 patients symptomatic for SARS-CoV-2 infection, Marinho *et al* described possible COVID-19 related retinal microvascular findings that could be associated with COVID-19 neurological events.<sup>14</sup> These lesions include cotton wool spots (CWS) and microhaemorrhages, as well as hyper-reflective lesions at the level of ganglion cell and inner plexiform layers in optical coherence tomography (OCT).

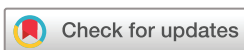While these retinal microvascular findings could be a manifestation of the prothrombotic and proinflammatory state of COVID-19, concerns were raised<sup>15</sup> about whether these non-specific findings could be confounded by pre-existing medical conditions. Furthermore, as there was no near-infrared reflectance (NIR) registration of these OCT images, it has been suggested that these findings were consistent with normal retinal vasculature from the superficial vascular plexus seen as hyper-reflective bands. Landecho *et al* evaluated 27 asymptomatic subjects with previous COVID-19 respiratory tract infection and found that six of them had CWS, of which 50% of them had hypertension and 17% of them had diabetes.<sup>16</sup> Retinopathy has been well-studied to have strong associations with systemic disorders such as hypertensive disorders,<sup>9</sup> elevated blood glucose<sup>18</sup> and renal dysfunction,<sup>13</sup> conditions that may pre-exist in older patients with COVID-19 infection. In a series of 44 672 patients with COVID-19 infection, 4.2% had coexisting cardiovascular disease and 12.8% had hypertension, while 53% had no data on comorbidities.<sup>19</sup>

Thus, it remains unclear as to whether retinal microvascular findings are more common and are indeed associated with COVID-19 infection or are incidental findings related to underlying systemic disease. To test the hypothesis that these retinal microvascular findings could be a reflection of the underlying cardiovascular and thrombotic alterations in COVID-19 infection, we describe the prevalence of these retinal signs, documented with colour fundus photographs (CFP) and OCT, and their relation to abnormal systemic vital signs and symptoms in a large series of largely healthy adult males with COVID-19.

## MATERIALS AND METHODS

This is a prospective, uncontrolled cross-sectional study of patients with COVID-19 conducted between 16 June and 21 June 2020.

We included patients aged 21–100 years old who tested positive for COVID-19 and informed consent was obtained from all patients. Consent forms were translated into Bengali and Tamil, the main language of the participants. Trained translators on site were



© Author(s) (or their employer(s)) 2021. No commercial re-use. See rights and permissions. Published by BMJ.

**To cite:** Sim R, Cheung G, Ting D, *et al*. *Br J Ophthalmol* Epub ahead of print: [please include Day Month Year]. doi:10.1136/bjophthalmol-2020-318236

on standby should further translation assistance be required. All patients had confirmed COVID-19 infection as determined by at least one positive result for SARS-CoV-2 from nasopharyngeal swab using real-time reverse-transcriptase PCR (RT-PCR). All diagnostic tests used in this study have undergone approval by the Health Sciences Authority (HSA) in Singapore, based on a risk-calibrated review process that considers the design aspects of the test (eg, primers and probe design, target sequence in the viral RNA) and the supporting validation data. Periodic reports on specific data on the safety and/or performance of these tests will be required to be submitted to HSA post-authorisation to assure the continued performance of these devices. If any safety or performance issues are observed, HSA will require relevant follow-up actions at the manufacturer's end. The study population consisted of largely younger, healthy residents who were migrant workers admitted to a community care facility in Singapore, which was used to housed COVID-19 positive patients with no other medical history and has mild or no symptoms, to recover with minimal intervention.

We excluded subjects who had any medical history or had any coexisting or previous ocular disease in either eye that may obstruct posterior eye imaging or confound possible COVID-19 retinal findings. Data on personal biodata, medical history, vital signs and oxygen saturation were collected from the electronic medical records. Vital signs were recorded on admission and daily during the period of the patient's stay in the facility. Elevated blood pressure (BP) was defined as systolic BP of 140 mm Hg and/or diastolic BP of 90 mm Hg, elevated heart rate (HR) was defined as HR  $\geq 100$  beats/min, hypoxaemia was defined as oxygen saturation or SpO<sub>2</sub>  $\leq 92\%$  on pulse oximetry, and tachypnoea was defined as respiratory rate  $>20$  breaths/min.

Retinal imaging was performed with an automated retinal imaging device (3D OCT-1 Maestro, Topcon, Tokyo, Japan) which can rapidly and non-invasively perform CFP and OCT. We used the 3DOCT-1 capture software (V.1.3.2.42308) and analysis software (V.8.4.2.41561). The operator was dressed in full personal protective equipment with N95 masks, face shield, gown, gloves and shoe cover. The machine chin rest and headband were wiped down with disinfectant wipes. Scan settings were standardised as follows: raster-scan composed of 256 $\times$ 256 (vertical $\times$ horizontal) axial scans covering an area of 6 $\times$ 6 mm in the macular region. Macular thickness measurements were generated by the analysis software in the nine regions of the Early Treatment Diabetic Retinopathy Study map, centred on the fovea. Retinal images were graded independently by two retinal specialists (CWW and YSY).

Statistical analysis was performed using standard statistical software: SPSS IBM SPSS Statistics V.26.0 (IBM). Continuous variables, such as retinal thickness, were presented as means $\pm$ SD. The  $\chi^2$  test and independent t-test were performed to evaluate the differences between the study groups. Bonferroni correction was performed to adjust for multiple comparisons of retinal thickness between groups. All p values reported were two-tailed and  $p < 0.05$  was considered to be statistically significant in this study.

## RESULTS

### Baseline characteristics

Table 1 shows the baseline clinical and demographic characteristics of our patients. One patient was excluded as he was underage (19 years old) and a total of six patients were excluded due to comorbidities: five had pre-existing hypertension and one had pre-existing diabetes and hyperlipidaemia. The ethnicity

**Table 1** Clinical and demographic characteristics of patient population

Total (n=108)	Retinal signs present (n=18)	Retinal signs absent (n=90)	P value
Age, years	35.2 $\pm$ 5.0	36.2 $\pm$ 5.4	0.75
Duration between PCR diagnosis and scan, days	15.9 $\pm$ 3.7	16.2 $\pm$ 3.6	0.99
Asymptomatic for COVID-19 infection, n (%)	10 (55.5)	57 (63.3)	0.54
Symptomatic for COVID-19 infection, n (%)	8 (44.4)	33 (36.7)	0.54
<b>Vital signs</b>			
Elevated BP, n (%)	9 (50)	22 (24.4)	0.03
Elevated HR, n (%)	0	9 (10)	0.16
At least one abnormal vital sign, n (%)	9 (50)	35 (38.9)	0.38

BP, blood pressure; HR, heart rate.

of the migrant population consisted largely of Bangladeshi (n=43; 39.8%) and Indian (n=62; 57.4%) nationals. Of the 108 enrolled subjects, the mean age was 36.0 $\pm$ 5.4 years (range 24–47 years). There were 18 patients (16.7%) with at least one eye with retinal findings. The mean duration of disease at entry to the study, defined as the period from RT-PCR positivity to study enrolment, was 16.1 $\pm$ 3.6 days. 41 (38.0%) had either symptoms of ARI, namely sore throat, cough or blocked/runny nose and/or symptoms specific to COVID-19 infection at presentation, namely anosmia (12, 11.1%) and taste disturbances such as ageusia (11, 10.1%). Thirteen patients (12.0%) had both symptoms of ARI as well as COVID-19.

Forty-four (40.7%) patients had abnormal vital signs: 35 (32.4%) had elevated BP (mean BP 144 $\pm$ 9/93 $\pm$ 6 mm Hg) and 13 (12.0%) had elevated HR of (mean HR 96 $\pm$ 8). Four (3.7%) patients had both elevated BP and HR. No patients in our study had a fever (defined as temperature  $\geq 38^\circ\text{C}$ ) or hypoxaemia (defined as oxygen saturation, or SpO<sub>2</sub>  $\leq 92\%$ ) or tachypnoea (respiratory rate  $>20$  breaths/min).

There was no significant difference in age ( $p=0.75$ ) or duration of COVID-19 infection ( $p=0.99$ ) between patients with or without retinal findings. The prevalence of retinal signs in patients symptomatic for COVID-19 infection was similar to asymptomatic patients (8 (44.4%) vs 10 (55.5%)  $p=0.54$ ). While there was no difference in the prevalence of elevated HR ( $p=0.16$ ) or at having at least one abnormal vital sign ( $p=0.38$ ) between patients with or without retinal signs, there was a significant correlation of elevated BP alone in patients with retinal signs as opposed to without ( $p=0.03$ ).

Out of the 18 patients with retinal findings, 7 (38.9%) were asymptomatic patients with normal vital signs. There was also no association between retinal signs and abnormal vitals ( $p=0.38$ ) and no association between retinal signs and presence of ARI or COVID-19 symptoms ( $p=0.54$ ). On conclusion of the study, all patients with elevated BP and retinal signs (mean BP 145 $\pm$ 11/90 $\pm$ 12 mm Hg), has BP that normalised without any medical intervention (mean BP 123.8 $\pm$ 6/84 $\pm$ 6 mm Hg). None of the patients required an escalation of care within the duration of the study.

### Retinal findings

Among 216 eyes, 25 (11.6%) had retinal signs on CFP and/or OCT. Retinal findings were bilateral in nine (50%) patients. These included eight eyes (3.7%) with microhaemorrhages, six eyes (2.8%) with retinal vascular tortuosity and two eyes (0.93%) with CWS. Eleven eyes (5.1%) had hyper-reflective plaques in the ganglion cell layer on OCT, of which two also

**Table 2** Distribution of retinal signs in patients with normal and abnormal BP

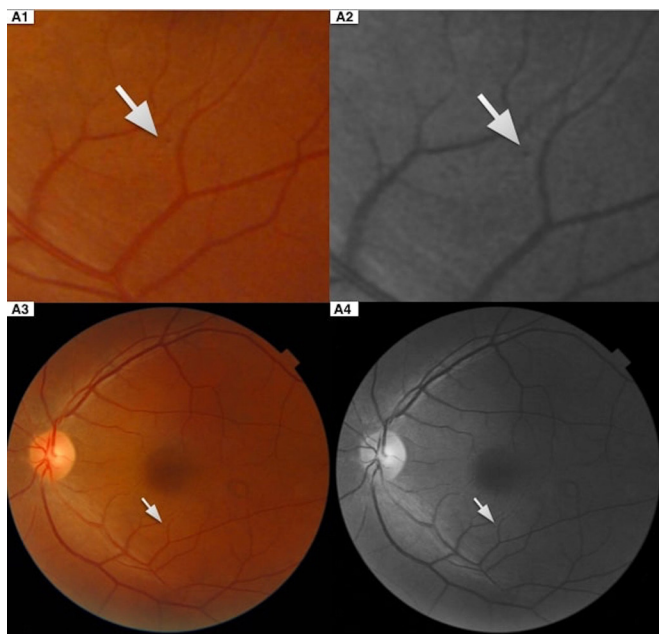
Retinal signs	Elevated BP (n=35)	Normal BP (n=73)	P value
<b>Fundus findings</b>			
Retinal haemorrhage, n (%)	3 (8.57)	3 (4.11)	0.34
Cotton wool spots, n (%)	0 (0)	1 (1.37)	0.49
Vascular tortuosity, n (%)	2 (5.71)	1 (1.37)	0.20
<b>OCT findings</b>			
Hyper-reflective plaques, n (%)	4 (11%)	6 (8.22%)	0.59

BP, blood pressure; OCT, optical coherence tomography.

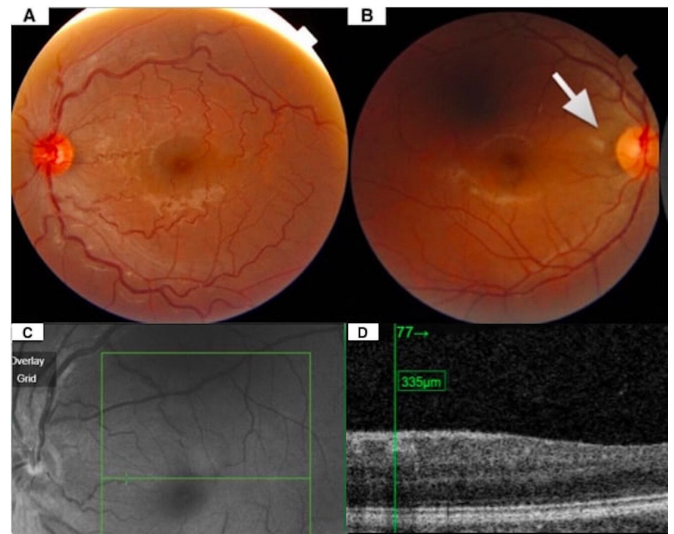
had retinal signs visible on CFP (CWS and microhaemorrhage, respectively). None of these eyes displayed any signs of vitritis, retinitis or vasculitis. As shown in [table 2](#), there was no significant difference in the prevalence of any of these retinal findings: retinal haemorrhage ( $p=0.34$ ), CWS ( $p=0.49$ ), vascular tortuosity ( $p=0.20$ ), hyper-reflective plaques ( $p=0.59$ ) in patients with or without elevated BP.

The retinal microhaemorrhages were situated throughout the fundus, with no specific predilection for any location ([figure 1](#)). In three eyes, there was an isolated microhaemorrhage that was noted in the inferior perifovea region. In two eyes, an isolated microhaemorrhage was noted in the inferior parafovea region. In two eyes, an isolated microhaemorrhage was noted in the superior perifovea region. In one eye, an isolated microhaemorrhage was noted in the superotemporal perifovea region.

In eyes with vascular tortuosity ([figure 2A](#)), the tortuosity appeared to be generalised, affecting was both the superior and inferior vascular arcades. CWS ([figure 2B](#)) were observed in both eyes of the same patient and were located in the temporal



**Figure 1** Magnified view of retinal microhaemorrhage (white arrow) seen on colour fundus photograph (A1) and red-free image (A2) and the corresponding original colour fundus (A3) and red-free image (A4) in the left eye of a patient asymptomatic for COVID-19 infection, with maximum BP reading of systolic 153 mm Hg and diastolic 103 mm Hg. The patient's blood pressure normalised to less than 120/90 mm Hg at the end of our study without any intervention.



**Figure 2** Colour fundus photograph showing the left eye with tortuous retinal vessels (A) of a patient asymptomatic for COVID-19 infection, who had a maximum blood pressure (BP) of systolic 151 mm Hg and diastolic 95 mm Hg. The patient's BP normalised to less than 120/90 mm Hg at the end of our study without any intervention. Colour fundus photograph (B) showing a peripapillary cotton wool spot (white arrow) of the right eye of a patient who presented with taste disturbances and runny nose. The patient's BP was consistently lower than systolic 140 and diastolic 90 mm Hg throughout the admission. A corresponding near infra-red reflectance image (C) of hyper-reflective lesions at the level of the inner plexiform and ganglion cell layers observed on optical coherence tomography B scan (D) in a patient asymptomatic for COVID-19 infection. The patient had a maximum BP reading of systolic 153 mm Hg and diastolic 120 mm Hg and the BP normalised to less than 120/90 mm Hg at the end of our study without any intervention.

peripapillary region. In OCT, hyper-reflective plaques in the ganglion cell layer ([figure 2C,D](#)), were flat, elongated bands with posterior shadowing.

[Table 3](#) shows the topographical distribution of retinal thickness in eyes with and without retinal findings. No significant differences were found between the two groups.

**Table 3** A comparison of mean retinal thickness in eyes with and without retinal findings

Retinal thickness, $\mu\text{m}$	Retinal signs present (n=25)	Retinal signs absent (n=191)	P value
Mean macula	274.7 $\pm$ 15.9	273.5 $\pm$ 13.3	>0.99
Centre subfield	192.5 $\pm$ 25.0	184.4 $\pm$ 25.1	>0.99
<b>Outer 6 mm</b>			
Superior	264.1 $\pm$ 25.5	266.9 $\pm$ 18.2	>0.99
Inferior	273.6 $\pm$ 19.4	266.4 $\pm$ 17.1	0.50
Nasal	287.6 $\pm$ 15.3	286.7 $\pm$ 15.2	>0.99
Temporal	255.9 $\pm$ 16.5	253.4 $\pm$ 14.5	>0.99
<b>Inner 3 mm</b>			
Inferior	302.2 $\pm$ 18.8	300.7 $\pm$ 16.5	>0.99
Nasal	300.9 $\pm$ 20.4	297.0 $\pm$ 18.7	>0.99
Superior	299.5 $\pm$ 26.8	298.3 $\pm$ 23.4	>0.99
Temporal	290.2 $\pm$ 26.8	288.4 $\pm$ 16.6	>0.99

## DISCUSSION

In our study, we demonstrate that retinal microvascular signs were seen in one in nine eyes (11.6%) in a cohort of young patients with COVID-19 with no previously diagnosed comorbidities to otherwise account for such findings. These signs include retinal microhaemorrhages, CWS and vascular tortuosity seen on CFP as well as hyper-reflective plaques found on OCT. We did not detect risk factors that may account for these retinal signs; age, presence or absence of COVID-19 symptoms, abnormal vital signs and duration from diagnosis did not differ between patients with or without retinal signs. Interestingly, one in three with retinal findings were asymptomatic patients with normal vital signs. Although BP was elevated in some patients at presentation, BP in all patients with retinal findings normalised by the conclusion of the study.

In a recently published case series of 12 patients with COVID-19, in which CWS, microhaemorrhages and hyper-reflective lesions in the inner retina detected on OCT were attributed to possible central nervous system alterations related to SARS-CoV-2 infection.<sup>14</sup> However, a subsequently published editorial<sup>15</sup> raised concerns with regards to the interpretation of those results. First, the OCT findings described may simply represent normal retinal vessels, and second, the fundus findings could be manifestations of pre-existing comorbid conditions. After all, retinal haemorrhages and CWS, are findings commonly found in patients with cardiovascular diseases, hypertension and vascular diseases.<sup>9 17</sup> In our study, we performed NIR registration of OCT images to confirm that all hyper-reflective plaques reported in our study do not correspond to normal retinal vessels. Furthermore, we have excluded patients with any comorbidities from our study that could confound the presence of retinal findings. For patients with retinal signs and elevated BP, we monitored their BP throughout their stay and found that BP normalised in all of these patients, confirming the absence of undiagnosed hypertension.

Similar retinal microvascular findings have previously been studied in cohorts of individuals with no diabetes. These studies spanning different demographics and ethnic groups have consistently reported a prevalence of retinal microvascular signs that was lower than our cohort of patients with COVID-19. Examples include the Atherosclerosis Risk In Communities study (n=15 792), the Singapore Indian Eye Study (n=1900) and the Singapore Malay Eye Study (n=2500), in which the prevalence of retinopathy are 4.8%, 5.05% and 6.0%, respectively.<sup>20-22</sup> In our cohort of patients with COVID-19, the prevalence of retinopathy is 11.6%, twice higher than the expected prevalence in individuals without cardiovascular risk factors, suggesting that COVID-19 infection itself could be associated with a higher prevalence of retinopathy. These signs are frequently associated with systemic disease and have been shown to be risk factors for other systemic vascular disorders. These systemic diseases include thrombotic or cardioembolic stroke,<sup>23 24</sup> cognitive decline,<sup>25 26</sup> hypertension<sup>9</sup> and renal dysfunction.<sup>13</sup>

Hypercoagulability is a known phenomenon in patients with COVID-19 that may have contributed to the retinal findings in our study. The pathogenesis of coagulopathy in COVID-19 has been attributed to direct viral infection and damage of endothelial cells, coupled with complement-mediated endothelial injury which may lead to microangiopathy and local thrombus formation.<sup>27 28</sup> The hypercoagulable state of a COVID-19 patient may explain the findings of retinal microhaemorrhages and vascular tortuosity seen in our study, reminiscent of retinal vascular occlusion.<sup>29</sup> Further studies may aid in elucidating the link between retinal signs and the prothrombotic state in COVID-19.

Transiently elevated BP was noted to be significantly more common in patients with retinal signs. Elevated BP manifests in the retinal vasculature with classic retinal vascular changes, such as retinal haemorrhages and CWS, as well as changes in retinal vascular calibre.<sup>30</sup> In the context of COVID-19, transiently elevated BP induced by COVID-19 infection may cause endothelial damage, producing the retinal microvascular signs seen in our patients.

COVID-19 related cardiovascular manifestations may be the result of a systemic proinflammatory state.<sup>31</sup> Acute viral infections have been known to cause a significant systemic inflammatory response plus localised vascular inflammation at the arterial plaque level.<sup>32 33</sup> While there is still a lack of such analyses in the retina, given the systemic involvement of the disease and the prevalence of ACE2 in retinal vessels, it may be possible that the retinal findings in our study are likewise a manifestation of this proinflammatory state.

Valsalva retinopathy due to severe coughing could be a possible alternative mechanism for retinal findings in patients with COVID-19. However, Valsalva retinopathy is characterised by macular preretinal haemorrhages, resulting from rupture of small superficial capillaries due to increased venous pressure,<sup>34</sup> whereas our patients presented mostly with retinal signs that resemble microvascular disease. In addition, there were no significant differences in retinal findings between patients with or without ARI symptoms.

We did not find any significant correlation between retinal thickness and retinal findings. In a recent case report of a patient with confirmed COVID-19 and bilateral acute conjunctivitis, macular ultrastructure and thickness readings measured on optical coherence tomography were within normal range.<sup>35</sup> Taken together, current evidence suggests that macular thickness may not be significantly affected in COVID-19 infection.

The strength of our study lies in the retinal imaging of the largest cohort of patients with COVID-19 to date. By including only younger patients without medical history, the possibility of the observed retinal findings being pre-existing lesions was reduced, although not completely eliminated. To further mitigate this possibility, we monitored the BP of all patients who presented with elevated BP over time and found that BP normalised at the end of the study. Furthermore, all migrant workers in Singapore have to undergo a formal compulsory pre-employment screening (mandated by our Ministry of Manpower) which includes BP and screening for diabetes mellitus and hence those with pre-existing comorbidities would have been identified in the process.

Our study has limitations. First, our study population consisted entirely of young healthy men, thereby restricting the generalisability of our findings, possibly introducing a selection bias by excluding older individuals. Second, due to the constraints of infection control measures, we could not perform visual acuity in these patients. However, no patients had subjective symptoms of decreased vision. Third, the cross-sectional nature of our study, with a lack of follow-up precluded the observation of the retinal lesions over time. Fourth, it would be ideal to perform additional haematological studies, such as D-dimer, prothrombin time to investigate the possibility of COVID-19 hyper-coagulopathy as a mechanism for the retinal signs as well as laboratory markers of inflammation such as C reactive protein to correlate the retinal findings with underlying systemic inflammation. Also, we acknowledge that while no significant difference was observed between patients with or without elevated BP, it could still be a contributing factor, which can be confirmed with a larger study or with patients with pre-existing elevated BP. In addition, our use of CFP, as opposed to wide-field imaging, provides relatively

limited visualisation of the peripheral retina and hence might not be able to capture peripheral lesions. Finally but not least, we acknowledge that a case–control study evaluating retinal findings in an uninfected population of a similar cohort of migrant workers or comparing the retinal findings in patients with other viral illnesses would be useful. However, we were limited in the study design by the rapidly evolving nature of the pandemic in Singapore and the strict infection control and containment measures imposed.

In conclusion, our study showed that one in nine eyes of patients with COVID-19 had retinal microvascular signs on ocular imaging. These retinal microvascular lesions are commonly found in patients with diabetes, hypertension and cardiovascular diseases and may reflect heightened cardiovascular and thrombotic alterations seen in COVID-19. Longitudinal studies in larger cohorts are needed to elucidate the natural history of these retinal lesions and to evaluate their relationship with the underlying systemic alterations in COVID-19 infection.

**Acknowledgements** The authors acknowledge the following who have contributed to this project: from Community Care Facility (CCF) @ Expo: Prof Tan Hiang Khoon, Dr Chow Weien, Professor Henry Ho, Professor Julian Thumboo, Dr Terrence Chiew, Sister Lee Lai Chee, Sister Ang Shin Yuh, Mr Lim Chee Tiong and Mr Issac Chua Sing. Health Office of Research: Dr Si Hoe San Ling. From Singapore Eye Research Institute (SERI): Ms Jillessica Lee and Stella Ng. From Topcon Singapore: Mr Gary Chow, Mr Ang Jun Yong and Mr Joeshua Lim. Translation team: Ms Kathryn Ng and Mr Vijaya Rao, Mr Mohamed Farook.

**Contributors** CWW was involved in literature review, protocol development, gaining ethical approval and conceiving the study. IYSY, CWW and RS were involved in patient recruitment, data collection and data analysis. CWW and RS wrote the first draft of the manuscript. All authors reviewed and edited the manuscript and approved the final version of the manuscript.

**Funding** The authors have not declared a specific grant for this research from any funding agency in the public, commercial or not-for-profit sectors.

**Competing interests** None declared.

**Patient consent for publication** Not required.

**Ethics approval** Our study was conducted following the ethical principles that have their origin in the Declaration of Helsinki and that are consistent with the Good Clinical Practice and the applicable regulatory requirements and approval by the SingHealth Research Centralised Institutional Review Board (CIRB reference number: 2020/2490) was obtained.

**Provenance and peer review** Not commissioned; externally peer reviewed.

**Data availability statement** Data are available upon reasonable request. Deidentified participant data will be available upon reasonable request.

This article is made freely available for use in accordance with BMJ's website terms and conditions for the duration of the covid-19 pandemic or until otherwise determined by BMJ. You may use, download and print the article for any lawful, non-commercial purpose (including text and data mining) provided that all copyright notices and trade marks are retained.

#### ORCID iDs

Ralene Sim <http://orcid.org/0000-0002-6972-8222>  
 Gemmy Cheung <http://orcid.org/0000-0003-3358-3516>  
 Daniel Ting <http://orcid.org/0000-0003-2264-7174>  
 Tien Yin Wong <http://orcid.org/0000-0002-8448-1264>  
 Ian Yeo <http://orcid.org/0000-0002-4385-2145>

#### REFERENCES

- World Health Organization. Coronavirus (COVID-2019) situation reports. Available: <https://www.who.int/emergencies/diseases/novel-coronavirus-2019/situation-reports/> [Accessed 30 Jun 2020].
- Merkler AE, Parikh NS, Mir S, et al. Risk of ischemic stroke in patients with coronavirus disease 2019 (COVID-19) vs patients with influenza. *JAMA Neurol* 2020. doi:10.1001/jamaneurol.2020.2730. [Epub ahead of print: 02 Jul 2020].
- Helms J, Tacquard C, Severac F, et al. High risk of thrombosis in patients with severe SARS-CoV-2 infection: a multicenter prospective cohort study. *Intensive Care Med* 2020;46:1089–98. doi:10.1007/s00134-020-06062-x
- Zhang Y, Xiao M, Zhang S, et al. Coagulopathy and antiphospholipid antibodies in patients with Covid-19. *N Engl J Med* 2020;382:e38.
- Klok FA, Kruijff MJHA, van der Meer NJM, et al. Incidence of thrombotic complications in critically ill ICU patients with COVID-19. *Thromb Res* 2020;191:145–7.
- Oxley TJ, Mocco J, Majidi S, et al. Large-Vessel stroke as a presenting feature of Covid-19 in the young. *N Engl J Med* 2020;382:e60.
- Bellosta R, Luzzani L, Natalini G, et al. Acute limb ischemia in patients with COVID-19 pneumonia. *J Vasc Surg* 2020;72:1864–72. doi:10.1016/j.jvs.2020.04.483
- Bilaloglu S, Aphinyanaphongs Y, Jones S, et al. Thrombosis in hospitalized patients with COVID-19 in a new York City health system. *JAMA* 2020;324:799–801. doi:10.1001/jama.2020.13372
- Wong TY, Wong T, Mitchell P. The eye in hypertension. *Lancet* 2007;369:425–35. Erratum in: *Lancet*. 2007 Jun 23;369(9579):2078. Wong, Tien [corrected to Wong, Tien Yin].
- Cheung N, Mosley T, Islam A, et al. Retinal microvascular abnormalities and subclinical magnetic resonance imaging brain infarct: a prospective study. *Brain* 2010;133:1987–93.
- Wong TY, Klein R, Couper DJ, et al. Retinal microvascular abnormalities and incident stroke: the Atherosclerosis risk in Communities study. *Lancet* 2001;358:1134–40.
- Yatsuya H, Folsom AR, Wong TY, et al. Retinal microvascular abnormalities and risk of lacunar stroke: atherosclerosis risk in Communities study. *Stroke* 2010;41:1349–55.
- Wong TY, Coresh J, Klein R, et al. Retinal microvascular abnormalities and renal dysfunction: the Atherosclerosis risk in Communities study. *J Am Soc Nephrol* 2004;15:2469–76.
- Marinho PM, Marcos AAA, Romano AC, et al. Retinal findings in patients with COVID-19. *Lancet* 2020;395:1610.
- Vavvas DG, Sarraf D, Sadda SR, et al. Concerns about the interpretation of OCT and fundus findings in COVID-19 patients in recent Lancet publication. *Eye* 2020;34:2153–4.
- Landeche MF, Yuste JR, Gándara E. COVID-19 retinal microangiopathy as an in vivo biomarker of systemic vascular disease? *J Intern Med* 2020.
- Wong TY, Hubbard LD, Klein R, et al. Retinal microvascular abnormalities and blood pressure in older people: the cardiovascular health study. *Br J Ophthalmol* 2002;86:1007–13.
- Wong TY, Liew G, Tapp RJ, et al. Relation between fasting glucose and retinopathy for diagnosis of diabetes: three population-based cross-sectional studies. *Lancet* 2008;371:736–43. Erratum in: *Lancet*. 2008 May 31;371(9627):1838.
- CDC Weekly C. The epidemiological characteristics of an outbreak of 2019 novel coronavirus diseases (COVID-19): China, 2020. *China CDC Weekly* 2020;2:113–22.
- Wong TY, Mohamed Q, Klein R, et al. Do retinopathy signs in non-diabetic individuals predict the subsequent risk of diabetes? *Br J Ophthalmol* 2006;90:301–3.
- Bhargava M, Cheung CY-lui, Sabanayagam C, et al. Prevalence and risk factors for retinopathy in persons without diabetes: the Singapore Indian eye study. *Acta Ophthalmol* 2014;92:e602–9.
- Jeganathan VSE, Cheung N, Tay WT, et al. Prevalence and risk factors of retinopathy in an Asian population without diabetes: the Singapore Malay eye study. *Arch Ophthalmol* 2010;128:40–5.
- Cheung N, Mosley T, Islam A, et al. Retinal microvascular abnormalities and subclinical magnetic resonance imaging brain infarct: a prospective study. *Brain* 2010;133:1987–93.
- Ong Y-T, De Silva DA, Cheung CY, et al. Microvascular structure and network in the retina of patients with ischemic stroke. *Stroke* 2013;44:2121–7.
- Wong TY, Klein R, Sharrett AR, et al. Retinal microvascular abnormalities and cognitive impairment in middle-aged persons: the Atherosclerosis risk in Communities study. *Stroke* 2002;33:1487–92.
- Lesage SR, Mosley TH, Wong TY, et al. Retinal microvascular abnormalities and cognitive decline: the ARIC 14-year follow-up study. *Neurology* 2009;73:862–8.
- Ackermann M, Verleden SE, Kuehnel M, et al. Pulmonary vascular Endothelialitis, thrombosis, and angiogenesis in Covid-19. *N Engl J Med* 2020;383:120–8.
- Nahum J, Morichau-Beauchant T, Daviaud F, et al. Venous thrombosis among critically ill patients with coronavirus disease 2019 (COVID-19). *JAMA Netw Open* 2020;3:e2010478.
- Recchia FM, Carvalho-Recchia CA, Hassan TS. Clinical course of younger patients with central retinal vein occlusion. *Arch Ophthalmol* 2004;122:317–21.
- Cheung CY-lui, Ikram MK, Sabanayagam C, et al. Retinal microvasculature as a model to study the manifestations of hypertension. *Hypertension* 2012;60:1094–103.
- Mondal R, Lahiri D, Deb S, et al. COVID-19: are we dealing with a multisystem vasculopathy in disguise of a viral infection? *J Thromb Thrombolysis* 2020;50:567–79.
- Madjid M, Aboshady I, Awan I, et al. Influenza and cardiovascular disease: is there a causal relationship? *Tex Heart Inst J* 2004;31:4–13.
- Corrales-Medina VF, Madjid M, Musher DM. Role of acute infection in triggering acute coronary syndromes. *Lancet Infect Dis* 2010;10:83–92.
- Duane TD. Valsalva hemorrhagic retinopathy. *Trans Am Ophthalmol Soc* 1972;70:298–313.
- Chen L, Liu M, Zhang Z, et al. Ocular manifestations of a hospitalised patient with confirmed 2019 novel coronavirus disease. *Br J Ophthalmol* 2020;104:748–51.